

# Analysis of Isocitrate Dehydrogenase (IDH) expression in astrocytoma patients: cases of South Sulawesi, Indonesia

*by Upik Miskad*

---

**Submission date:** 15-Jul-2022 08:39AM (UTC+0700)

**Submission ID:** 1870667260

**File name:** Publikasi14\_1.pdf (381.9K)

**Word count:** 3981

**Character count:** 22121

## Analysis of Isocitrate Dehydrogenase (IDH) expression in astrocytoma patients: cases of South Sulawesi, Indonesia



Olivia Desty Sabunga<sup>1\*</sup>, Cahyono Kaelan<sup>1</sup>, Upik Anderiani Miskad<sup>1</sup>, Andi Alfian Zainuddin<sup>1,2</sup>, Ni Ketut Sungowati<sup>1</sup>, Muhammad Husni Cangara<sup>1</sup>

22

## ABSTRACT

**Background:** Astrocytoma is the most common primary intracerebral tumor in adults and causes high morbidity and mortality. Most patients with astrocytomas, especially diffuse gliomas, have a poor prognosis. Recent genetic and epigenetic studies have shown that mutations in the Isocitrate Dehydrogenase (IDH) gene play an important role in the pathogenesis and prognosis of gliomas, thus facilitating IDH1 mutations in the population to become an important marker, not only to assist in the diagnosis and prognostic factors of these gliomas but also to develop therapeutic targets as currently available. This study aims to see differences in the expression of the IDH in each astrocytoma classification.

**Methods:** A cross-sectional analytic study was conducted at the Anatomical Pathology Laboratory, Faculty of Medicine, Universitas Hasanuddin, from October 2020 to just 2021. The research sample came from 65 paraffin block preparations for primary brain tumors with the diagnosis of Diffuse Astrocytoma (DA), Anaplastic Astrocytoma (AA) and Glioblastoma (GB). The immunohistochemical staining was performed using the monoclonal antibody IDH1-R132H. The microscopic assessment was carried out using a light microscope. Data were analyzed using SPSS version 20 for Windows.

**Results:** There was a significant relationship between the expression of IDH1-R132H in each astrocytoma classification ( $p=0.008$ ). The prevalence of astrocytoma with negative IDH1-R132H expression (IDH-wildtype) is lower by 21 samples (32.3%) compared to astrocytoma with positive IDH1-R132H expression (IDH-mutant), which is 44 samples (67.7%).

**Conclusion:** There are significant differences in the expression of IDH1-R132H in Diffuse Astrocytoma, Anaplastic Astrocytoma and Glioblastoma, where the proportion of IDH-mutant status is higher than IDH-wildtype and IDH1 mutation status has a significant relationship with tumor grade.

**Keywords:** IDH-R132H, IDH-mutant, IDH-wildtype, astrocytoma.

**Cite This Article:** Sabunga, O.D., Kaelan, C., Miskad, U.A., Zainuddin, A.A., Sungowati, N.K., Cangara, M.H. 2022. Analysis of Isocitrate Dehydrogenase (IDH) expression in astrocytoma patients: cases of South Sulawesi, Indonesia. *Bali Medical Journal* 11(1): 184-188. DOI: 10.15562/bmj.v11i1.3078

<sup>1</sup>Department of Pathology Anatomy, Universitas Hasanuddin, Makassar, Indonesia;

<sup>2</sup>Department of Public Health, Universitas Hasanuddin, Makassar, Indonesia;

\*Corresponding author:

Olivia Desty Sabunga;  
Department of Pathology Anatomy,  
Universitas Hasanuddin, Makassar,  
Indonesia;

olviasabunga@gmail.com

Received: 2022-01-07

Accepted: 2022-03-28

Published: 2022-04-08

## INTRODUCTION

Brain cancer accounts for about 85-90% of central nervous system cancers.<sup>1</sup> Malignant primary brain tumors are significantly lower in East Asia, Southeast Asia, and India. The highest incidence is found in Europe, Canada, the United States, and Australia. Data from Globocan 2018 shows the worldwide incidence of brain and nervous system tumors is 308,000 (1.6%), with a mortality rate of 251,000.<sup>1</sup> Anaplastic astrocytomas and glioblastomas account for about 38% of all primary central nervous system tumors, and 27% are meningiomas and other mesenchymal tumors.<sup>2</sup> The other primary brain tumors include pituitary tumors, schwannomas, CNS lymphomas, oligodendrogliomas,

ependymomas, low-grade astrocytomas, and medulloblastomas. There is no clear national epidemiological data regarding primary brain tumors in Indonesia, especially astrocytomas.<sup>2,3</sup>

Astrocytoma is the most common primary intracerebral tumor in adults and causes high morbidity and mortality. Most patients with astrocytomas, especially diffuse gliomas, have a poor prognosis.<sup>4</sup> Astrocytomas are classified into subtypes according to glial cell histology. They are divided into grades 1 to 4 based on morphology and malignant behavior as well as molecular information as determined in the World Health Organization (WHO) 2016 classification. High-grade glioma (HGG), also called malignant glioma, has rapid tumor growth

but rarely metastasize outside the CNS. Glioblastomas are included in the WHO grade 4 HGG, with an incidence of about 75% of all HGG.<sup>4</sup>

The change in classification by including molecular parameters based on genotype creates new challenges concerning testing and reporting glioma diagnoses. This 2016 classification updates molecular parameters into diffuse gliomas, and this shift has affected the classification in several ways. All astrocytic tumors were previously grouped. At present, however, all diffuse gliomas (astrocytic origin or not) are grouped, based on not only their growth pattern and behavior but also on the expression of genetic status Isocitrate Dehydrogenase 1 and 2 (IDH1 and IDH2).<sup>5</sup>

In this new classification, the category of diffuse glioma includes WHO grade 1 and 3 astrocytic tumors, grade 2 and 3 oligodendrogliomas, grade 2 and 3 oligoastrocytomas, grade 4 glioblastoma, and associated diffuse gliomas (in childhood). This approach separates astrocytomas with a more restricted growth pattern, lacks the IDH gene, occasionally has BRAF mutations (pilocytic astrocytomas, pleomorphic xanthoastrocytomas, and subependymal giant cell astrocytomas) from diffuse gliomas. IDH1 and IDH2 mutations are found in almost all glioblastomas that develop from astrocytomas (secondary glioblastomas).<sup>5,6</sup> Clinically, primary Glioblastoma with IDH1 mutations can be misclassified and may actually be an asymptomatic low-grade glioma that has developed and then become symptomatic after becoming a glioblastoma. Thus, the IDH1 mutation is a molecular marker that can be used to separate groups of glioblastomas that may be clinically or histopathologically identical to the secondary type.<sup>5,6</sup>

Recent genetic and epigenetic studies have shown that mutations in the IDH gene play an important role in the pathogenesis and prognosis of gliomas so that identification of IDH1 mutations in the sample population can be an important marker, not only to help diagnose and determine the prognosis of these gliomas but also for the development of targeted therapies such as chemotherapy.<sup>6</sup>

Based on those mentioned above, this study aims to evaluate the analysis of Isocitrate Dehydrogenase (IDH) expression in astrocytoma patients at South Sulawesi, Indonesia.

## MATERIAL AND METHODS

This study collected 65 paraffin block samples of patients by consecutive sampling technique. Patients with Diffuse Astrocytoma (DA), Anaplastic Astrocytoma (AA) and Glioblastoma (GB) from the Anatomical Pathology Laboratory of Wahidin Sudirohusodo Hospital, Universitas Hasanuddin Hospital, Makassar Pathology Diagnostic Center, Siloam Hospital Makassar, and Sawerigading Palopo Hospital during the period October 2020 to August 2021 were

collected.

Unstained slides were made from paraffin blocks and IDH1-R132H immunohistochemistry staining was performed. In each case, slides were made from paraffin blocks then cut with a 3 µm thick microtome. The cut in the water bath was taken using a poly-L-lysine slide, then deparaffinized-immunohistochemical staining using Rabbit anti-IDH1\_R132H Monoclonal Antibody.

IDH1-R132H expression was assessed on membrane and cytoplasm of tumor cells using a light microscope with 400x objective magnification by two pathologists who were blinded to clinical information and outcomes. IDH expressions were divided into 2 groups: IDH-mutant if IDH1 expression was 10% stained on the membrane and cytoplasm of tumor cells and IDH-wildtype if IDH1 expression <10% stained on the membrane and cytoplasm of tumor cells.<sup>7</sup>

The data in this study were processed using SPSS version 20 for Windows. Descriptive statistical techniques were used to describe the basic data obtained in the frequency distribution. Chi-Square tests were used to determine IDH1 expression in each astrocytoma classification.

## RESULTS

Of the 65 samples, the distribution of astrocytoma samples is based on

diagnoses in line with histopathological grading, gender, age, tumor location based on clinical or radiological data, and the molecular status of IDH1 R132-H shown in Table 1. Distribution of samples based on histopathological diagnosis, 22 samples (33.80%) of DA cases were obtained, 15 samples of AA (23.10%) and 28 samples of GB (43.10%) were found. From this total sample, there were 40 samples of male (61.50%) and 25 samples of female (38.50%) (Table 1).

In the age category 0-19 years, there were 9 samples (13.80%), for the age category 20-39 years, there were 24 samples (36.90%), for the age category 40-59 years, there were 22 samples (33.80%) and the age category >59 years obtained 10 samples (15.40%) (Table 1). For the location of the tumor, it was categorized into 2 locations as supratentorial with 53 samples (81.50%) and infratentorial with 12 samples (18.50%) (Table 1). The results of the examination using IDH1-R132H immunohistochemical staining, obtained 44 samples (67.70%) expressing IDH1-R132H >10% (positive/IDH-mutant) and 21 samples (32.30%) expressing IDH1-R132H <10% (negative/ IDH-wildtype) (Table 1). IDH1-R132H expression in astrocytoma can be seen in Figure 1.

From Table 2, the results of the correlation analysis test between age and astrocytoma diagnosis using the Chi-Square test show that p-value = 0.837

**Table 1. Sample distribution based on Demographics and Clinical Characteristics.**

Characteristics	Total (N=65)	Percentage (%)
Diagnosis		
Diffuse Astrocytoma (DA)	22	33.80
Anaplastic Astrocytoma (AA)	15	23.10
Glioblastoma (GB)	28	43.10
Gender		
Male	40	61.50
Female	25	38.50
Age (Years Old)		
0-19	9	13.80
20-39	24	36.90
40-59	22	33.80
> 59	10	15.40
Location		
Supratentorial	53	81.50
Infratentorial	12	18.50
IDH1-R132H		
> 10% (positive)/ mutant	44	67.70
< 10% (negative)/ wild-type	21	32.30

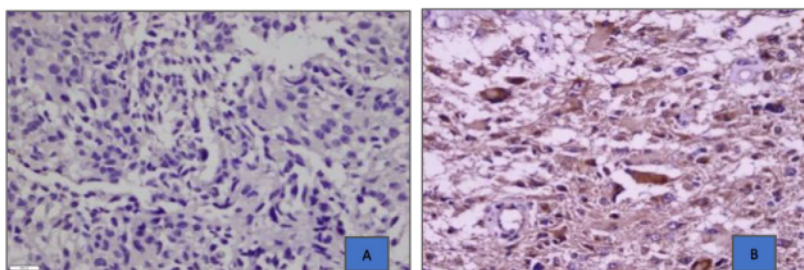
IDH: Isocitrate Dehydrogenase

( $p > 0.05$ ), which means that there is no significant relationship between age and astrocytoma diagnosis. In the age category 0-19 years, from a total of 9 samples, there were 3 samples (33.3%) with a diagnosis of diffuse astrocytoma, 1 sample (11.1%) with a diagnosis of anaplastic astrocytoma and 5 samples (55.6%) with a diagnosis of Glioblastoma. In the age category 20-39 years, from a total of 24 samples, there were 10 samples (41.7%) diagnosed as diffuse astrocytoma, 5 samples (20.8%) diagnosed as anaplastic astrocytoma and 9 samples (37.5%) diagnosed as

Glioblastoma. In the age category of 40-59 years, from a total of 22 samples, 6 samples (27.3%) were diagnosed with diffuse astrocytoma, 7 samples (31.8%) were diagnosed with anaplastic astrocytoma and 9 samples (40.9%) were diagnosed with Glioblastoma. In the age category >59 years, from a total of 10 samples, 3 samples (30.0%) were diagnosed with diffuse astrocytoma, 2 samples (20.0%) were diagnosed with anaplastic astrocytoma and 5 samples (50.0%) were diagnosed with Glioblastoma (Table 2).

In Table 3, the results of the correlation analysis test between the diagnosis of astrocytoma and the location of the tumor using the Chi-Square test were obtained, which showed p-value was 0.001 ( $p < 0.05$ ), which indicates that there was a significant relationship between the diagnosis of astrocytoma and the location of the tumor. For tumor samples with a diagnosis of diffuse astrocytoma, the most commonly found in supratentorial locations were 13 samples (59.1%). Similarly, most of them were found in supratentorial locations (80.0%). All glioblastoma tumor samples were located in supratentorial (100%), and no samples were located in Infratentorial.

Based on Table 4, the results of the correlation analysis test between the diagnosis of astrocytoma and the expression of IDH1-R132H using the Chi-Square test showed p value=0.008 ( $p < 0.05$ ), which means that there is a significant relationship between the diagnosis of astrocytoma and the molecular status of IDH1-R132H. Astrocytoma with negative IDH1-R132H expression was classified as IDH-wildtype, while astrocytoma with positive IDH1-R132H expression was



**Figure 1.** Expression of IDH1-R132H (Glioblastoma). A. Negative IDH1-R132H expression at 400x magnification. B. Expression of IDH1-R132H positively stained on the membrane and cytoplasm of tumor cells at 400x magnification.

**Table 2.** Characteristics of astrocytoma diagnosis based on age.

Age (years old)	Diagnosis			Total (%)	p
	DA (%)	AA (%)	GB (%)		
0-19	3 (33.3)	1 (11.1)	5 (55.6)	9 (100.0)	0.837*
20-39	10 (41.7)	5 (20.8)	9 (37.5)	24 (100.0)	
40-59	6 (27.3)	7 (31.8)	9 (40.9)	22 (100.0)	
>59	3 (30.0)	2 (20.0)	5 (50.0)	10 (100.0)	

\*Chi-Square Test: statistically significant if p-value less than 0.05

**Table 3.** Characteristics of astrocytoma diagnosis based on tumor location.

Diagnosis	Location (%)		Total (%)	p
	Supratentorial	Infratentorial		
DA	13 (59.1%)	9 (40.9%)	22 (100.0%)	0.001*
AA	12 (80.0%)	3 (20.0%)	15 (100.0%)	
GB	28 (100.0%)	0 (0%)	28 (100.0%)	

\*Chi-Square Test: statistically significant if p-value less than 0.05

**Table 4.** Relationship between astrocytoma diagnosis and expression of IDH1-R132H.

Diagnosis	IDH1-R132H expression (%)		Total (%)	p
	<10% (negative) IDH-wildtype (N=21)	>10% (positive) IDH-mutant (N=44)		
DA	12 (54.5)	10 (45.5)	22 (100.0)	0.008*
AA	1 (6.7)	14 (93.3)	15 (100.0)	
GB	8 (28.6)	20 (71.4)	28 (100.0)	

\*Chi-Square Test: statistically significant if p-value less than 0.05

classified as IDH-mutant. The prevalence of astrocytoma with negative IDH1-R132H expression (IDH-wildtype) is lower by 21 samples (32.3%) compared to astrocytoma with positive IDH1-R132H expression (IDH-mutant), which is 44 samples (67.7%) (Table 4).

In Table 4, it can be seen that from the total 22 samples of diffuse astrocytoma, there were 12 samples (54.5%) with negative IDH1-132H expression (IDH-wildtype diffuse astrocytoma) and 10 samples (45.5%) with positive IDH1-132H expression (IDH-mutant diffuse astrocytoma). From a total of 15 samples of anaplastic astrocytoma, there was only 1 sample (6.7%) with a negative IDH1-132H expression (IDH-wildtype anaplastic astrocytoma) and 14 samples (93.3%) with a positive IDH1-132H expression (IDH-mutant anaplastic astrocytoma). For the diagnosis of Glioblastoma, more IDH-mutant samples were obtained compared to IDH-wild-type samples. Of the total 30 samples of Glioblastoma, there were 8 samples (28.6%) with negative IDH1-132H expression (IDH-wildtype Glioblastoma) and 20 samples (71.4%) with positive IDH1-132H expression (IDH-mutant Glioblastoma) (Table 4).

## DISCUSSION

Astrocytoma is a primary brain tumor derived from astrocyte cells with a poor prognosis and the most frequent and aggressive incidence. In Indonesia, apart from surgery, other therapies have not been developed. In addition, tumor cells remaining after surgery are generally resistant to conventional therapies such as radiotherapy and chemotherapy so that astrocytoma patients show high therapeutic recurrence.<sup>8</sup>

The recent developments have added several molecular characteristics to the classification of astrocytoma. Although astrocytoma is a very heterogeneous disease, this molecular classification of astrocytomas may reflect their biologic behavior suggesting that tumors with similar expression profiles exhibit similar gene alterations<sup>15</sup> and signaling pathways. Identifying mutations in isocitrate dehydrogenase, 1/2 (IDH1/2) offers astrocytomas a better prognosis regardless of the histopathological

grade.<sup>12</sup> One hypothesis is that mutated IDH1 converts  $\alpha$ -ketoglutarate to 2-hydroxyglutarate, which in turn blocks various enzymes, thereby contributing to tumor development.<sup>7</sup>

The recent findings found that the most samples were Glioblastoma (43.10%) followed by diffuse astrocytoma (33.80%) and then anaplastic astrocytoma (23.10%). From this<sup>18</sup> sole sample, the highest incidence is in males compared to females with a ratio of 1.5:1. These data are in line with several previous studies, which found that the incidence of Glioblastoma was highest compared to other types of astrocytoma and was most common in males.<sup>4,9,10</sup>

In the age category, we found the highest prevalence of astrocytoma was in the age group of 20-59 years, and this result is in line with other studies. This shows that gliomagenesis occurs at a younger age in the 2nd to 5th decades with an average age of 39 years.<sup>10</sup> In the anaplastic astrocytoma and Glioblastoma, the frequency increased with age and decreased over the age of 59 years. This may be due to the low survival rate<sup>14</sup> astrocytoma patients. However, we did not find a statistically significant relationship between age and astrocytoma diagnosis.

There was a significant relationship between astrocytoma diagnosis and tumor location based on the tumor location. The most common location was supratentorial (81.50%) compared to infratentorial location (18.50%). This is in line with research conducted by Omer NS et al., who said that this could be due to the supratentorial<sup>13</sup> location containing the most glial cells.<sup>10</sup> Neural Stem Cells (NSCs) can be found in several locations in the adult brain, including the Subventricular Zone (SVZ), the dentate gyrus of the hippocampus, and the subcortical white matter. This SVZ is thought to be the origin of most of these cells and has been proposed to be the origin of gliomas and other brain tumors. Louis DN et al., also mentioned that Diffuse Astrocytoma (DA) can occur throughout the CNS but is usually located supratentorial and has an intrinsic tendency to develop into anaplastic astrocytoma and eventually to Glioblastoma.<sup>5</sup>

This study used a specific monoclonal

antibody to detect IDH1-R132H mutations. Based on several previous studies, immunohistochemical staining and sequencing accuracy for IDH1 mutation<sup>4</sup> detection ranged from 88% to 100%. Several studies have even shown that immunohistochemical staining is more sensitive in detecting IDH1 mutations than DNA sequencing, especially in tumor samples that are so small. However, several other studies have shown that DNA sequencing<sup>24</sup> a more sensitive test because the antibodies can only<sup>4</sup> detect the R132H mutation. In contrast, other mutations such as R132C, R132L, R132S, and R132G cannot be detected by immunohistochemical staining.<sup>11,12</sup>

We found that IDH1-R132H was positively expressed (IDH-mutant)<sup>23</sup> in 44 cases (67.70%) of astrocytomas. Our results are in line with studies conducted by Myung et al. and Wagn et al. The important point of these results is that in this study and several other studies, more secondary glioblastoma samples were included in the study resulting in higher positive IDH1-R132H expression. In contrast, the primary glioblastoma samples included had lower rates. This explains the importance of differentiating secondary Glioblastoma from primary Glioblastoma and confirms that this IDH1 expression pattern may indicate that secondary Glioblastoma has a longer survival rate. There are also different results of other studies in America, Australia and Europe, where the expression of negative IDH1 (IDH-wildtype) is higher (about 90%) compared to positive IDH1 (IDH-mutant). These different results are caused by different epidemiology and polymorphisms or the different methods used for IDH1 mutation detection.<sup>10,13,14</sup>

Table 4 shows a significant relationship between the diagnosis of astrocytoma and the molecular status of IDH1-R132H. These results prove that IDH1-R132H plays a role in the occurrence and development of astrocytoma. Huang J et al., revealed that IDH1 mutations give rise to new gene functions, decreasing<sup>129</sup> production of  $\alpha$ -KG and increasing the production<sup>17</sup> of D-2-Hydroxyglutarate (D-2HG).<sup>15</sup> D-2HG has a similar structure<sup>17</sup> to  $\alpha$ -KG, acts as an oncometabolite and competitively inhibits the activity of various dioxygenase

enzymes. In addition, this IDH1 mutation produces high levels of 2-hydroxyglutaric acid (2-HG), thereby inhibiting the differentiation of glioma stem cells. At the same time, IDH1 mutations can increase vascular endothelial growth factor (VEGF), which plays a role in forming the tumor microenvironment. In addition, IDH1 mutations can also induce HIF-1 $\alpha$  to trigger glioma invasion. Ultimately, these changes will lead to the development and pathogenesis of astrocytoma.<sup>15</sup>

In Table 4, we can see that the frequency of astrocytomas with a positive IDH1-R132H molecular status (IDH-mutant) will be higher in line with the increase in tumor grade compared to astrocytomas with negative IDH1-R132H molecular status (IDH-wildtype). IDH1 mutations were lowest in astrocytoma grade 2, which correlated with slow tumor growth and good survival. IDH1 mutations are highest in grade 4 gliomas or glioblastomas that correlate with rapid tumor growth and poor survival. In early 2008, Parsons DW et al., found an association between astrocytoma and IDH mutations in exon sequencing.<sup>16</sup> Parsons DW et al., found the IDH1 gene in 1/5 of the tumor samples.<sup>16</sup> Further studies have found that the IDH1-R132H mutation is the most frequent in astrocytoma. In contrast, the IDH2-R172H gene also undergoes a similar mutation, but the mutation frequency is relatively low.<sup>15</sup>

## CONCLUSION

There are significant differences in the expression of IDH1-R132H in Diffuse Astrocytoma, Anaplastic Astrocytoma and Glioblastoma, where the proportion of IDH-mutant status is higher than IDH-wildtype and IDH1 mutation status has a significant relationship with increasing tumor grade.

## CONFLICT OF INTEREST

There is no potential conflict of interest in this research.

## FUNDING

None.

## ETHICS APPROVAL

This research ethics committee approved this study of the Faculty of Medicine Hasanuddin University in 2021 with approval number 128/UN4.6.5.31/PP36/2021.

## AUTHOR CONTRIBUTIONS

ODS, CK, UAM, NKS and MHC prepared the concept, research design and data collection. ODS and AAZ were involved in data processing and analysis, as well as drafting articles. All authors reviewed draft articles.

## REFERENCES

- Bray F, Ferlay J, Soerjomataram I, Siegel RL, Torre LA, Jemal A. Global cancer statistics 2018: GLOBOCAN estimates of incidence and mortality worldwide for 36 cancers in 185 countries. *CA Cancer J Clin.* 2018;68(6):394-424.
- Bell JS, Koffie RM, Rattani A, Dewan MC, Baticulon RE, Qureshi MM, et al. Global incidence of brain and spinal tumors by geographic region and income level based on cancer registry data. *J Clin Neurosci.* 2019;66:121-127.
- Leece R, Xu J, Ostrom QT, Chen Y, Kruchko C, Barnholtz-Sloan JS. Global incidence of malignant brain and other central nervous system tumors by histology, 2003-2007. *Neuro Oncol.* 2017;19(11):1553-1564.
- Rasmussen BK, Hansen S, Laursen RJ, Kosteljanetz M, Schultz H, Nørgård BM, et al. Epidemiology of glioma: clinical characteristics, symptoms, and predictors of glioma patients grade I-IV in the the Danish Neuro-Oncology Registry. *J Neurooncol.* 2017;135(3):571-579.
- Louis DN, Perry A, Wesseling P, Brat DJ, Cree IA, Figarella-Branger D, et al. The 2021 WHO Classification of Tumors of the Central Nervous System: a summary. *Neuro Oncol.* 2021;23(8):1231-1251.
- DeWitt JC, Mock A, Louis DN. The 2016 WHO classification of central nervous system tumors: what neurologists need to know. *Curr Opin Neurol.* 2017;30(6):643-649.
- Malueka RG, Theresia E, Fitria F, Argo IW, Donurizki AD, Shaleh S, et al. Comparison of Polymerase Chain Reaction-Restriction Fragment Length Polymorphism, Immunohistochemistry, and DNA Sequencing for the Detection of IDH1 Mutations in Gliomas. *Asian Pac J Cancer Prev.* 2020;21(11):3229-3234.
- Gargini R, Segura-Collar B, Sánchez-Gómez P. Cellular Plasticity and Tumor Microenvironment in Gliomas: The Struggle to Hit a Moving Target. *Cancers (Basel).* 2020;12(6):1622.
- Metellus P, Colin C, Taieb D, Guedj E, Nanni-Metellus I, de Paula AM, et al. IDH mutation status impact on in vivo hypoxia biomarkers expression: new insights from a clinical, nuclear imaging and immunohistochemical study in 33 glioma patients. *J Neurooncol.* 2011;105(3):591-600.
- Omer NS, Jalal JA, Ismael AT. IDH1(R132H) Immunorexpression in Glioma. *Journal of Kurdistan Board of Medical Specialties.* 2018;4(1):57-63.
- Ichimura K. Molecular pathogenesis of IDH mutations in gliomas. *Brain Tumor Pathol.* 2012;29(3):131-139.
- Loussouarn D, Le Loupp AG, Frenel JS, Leclair F, Von Deimling A, Aumont M, et al. Comparison of immunohistochemistry, DNA sequencing and allele-specific PCR for the detection of IDH1 mutations in gliomas. *Int J Oncol.* 2012;40(6):2058-62.
- Sriwidyani NP, Wahyuniari IAI, Saputra H, Arijana IGKN. IDH1 mutation in Balinese glioma patients and its relationship with clinicopathological parameters. *Bali Medical Journal.* 2020;9(3):819-822.
- Yao Q, Cai G, Yu Q, Shen J, Gu Z, Chen J, et al. IDH1 mutation diminishes aggressive phenotype in glioma stem cells. *Int J Oncol.* 2018;52(1):270-278.
- Huang J, Yu J, Tu L, Huang N, Li H, Luo Y. Isocitrate Dehydrogenase Mutations in Glioma: From Basic Discovery to Therapeutics Development. *Front Oncol.* 2019;9:506.
- Parsons DW, Jones S, Zhang X, Lin JC, Leary RJ, Angenendt P, et al. An integrated genomic analysis of human glioblastoma multiforme. *Science.* 2008;321(5897):1807-12.



This work is licensed under a Creative Commons Attribution

# Analysis of Isocitrate Dehydrogenase (IDH) expression in astrocytoma patients: cases of South Sulawesi, Indonesia

## ORIGINALITY REPORT

19%

SIMILARITY INDEX

15%

INTERNET SOURCES

10%

PUBLICATIONS

1%

STUDENT PAPERS

## PRIMARY SOURCES

1	<a href="http://gssrr.org">gssrr.org</a> Internet Source	3%
2	<a href="http://www.frontiersin.org">www.frontiersin.org</a> Internet Source	2%
3	<a href="http://citeseerx.ist.psu.edu">citeseerx.ist.psu.edu</a> Internet Source	1%
4	<a href="http://journal.waocp.org">journal.waocp.org</a> Internet Source	1%
5	Baiq Ratna Kumaladewi, Willy Sandhika, Heryawati Heryawati. "Role of CD44 and CD8 in Colorectal Adenocarcinoma metastatic", Medical Laboratory Technology Journal, 2020 Publication	1%
6	<a href="http://ijbs-udayana.org">ijbs-udayana.org</a> Internet Source	1%
7	<a href="http://media.neliti.com">media.neliti.com</a> Internet Source	1%
8	<a href="http://Www.dovepress.com">Www.dovepress.com</a> Internet Source	

1 %

9

[www.science.gov](http://www.science.gov)

Internet Source

1 %

10

Shumei Jin, Cuiyun Sun, Shizhu Yu, Qian Wang, Weixiang Wu, Yajing Sun, Wenjuan Zhao, Tongling An. "Chromosome DNA imbalances in human astrocytic tumors: A comparative genomic hybridization study of 63 Chinese patients", Pathology - Research and Practice, 2010

Publication

1 %

11

[www.coursehero.com](http://www.coursehero.com)

Internet Source

1 %

12

Anita Huttner. "Overview of Primary Brain Tumors", Hematology/Oncology Clinics of North America, 2012

Publication

1 %

13

[baixardoc.com](http://baixardoc.com)

Internet Source

1 %

14

[is.muni.cz](http://is.muni.cz)

Internet Source

<1 %

15

[www.spandidos-publications.com](http://www.spandidos-publications.com)

Internet Source

<1 %

16

"Diffuse Low-Grade Gliomas in Adults", Springer Science and Business Media LLC,

<1 %

2017

Publication

17

Koichi Ichimura. "Molecular pathogenesis of IDH mutations in gliomas", Brain Tumor Pathology, 2012

Publication

<1 %

18

actascientific.com

Internet Source

<1 %

19

ijamscr.com

Internet Source

<1 %

20

Scott G. Soltys, Nadia N. Laack, Lia M. Halasz, Giuseppe Minniti, Michael D. Chan, John P. Kirkpatrick. "Treatment of WHO Grade 2 and 3 Gliomas With Potentially Favorable Survival: Is Monotherapy Obsolete?", International Journal of Radiation Oncology\* Biology\* Physics, 2019

Publication

<1 %

21

blog.balimedicaljournal.org

Internet Source

<1 %

22

translational-medicine.biomedcentral.com

Internet Source

<1 %

23

journals.plos.org

Internet Source

<1 %

24

Timucin Avsar, Alihan Sursal, Gizem Turan, Berfu Nur Yigit et al. "Development of a Rapid

<1 %

and Sensitive IDH1/2 Mutation Detection Method for Glial Tumors and a Comparative Mutation Analysis of 236 Glial Tumor Samples", Molecular Diagnosis & Therapy, 2020

Publication

25

VALERIE PARADIS, SOPHIE FERLICOT, ELIE GHANNAM, LEILA ZEIMOURA et al. "CD44 IS AN INDEPENDENT PROGNOSTIC FACTOR IN CONVENTIONAL RENAL CELL CARCINOMAS", Journal of Urology, 1999

Publication

<1 %

26

[jgrph.org](http://jgrph.org)  
Internet Source

<1 %

27

[mobt3ath.com](http://mobt3ath.com)  
Internet Source

<1 %

28

[pusbangdik.poltekkesdepkes-sby.ac.id](http://pusbangdik.poltekkesdepkes-sby.ac.id)  
Internet Source

<1 %

29

[www.jci.org](http://www.jci.org)  
Internet Source

<1 %

30

Rusdy Ghazali Malueka, Rachmat Andi Hartanto, Maria Alethea, Christina Megawimanti Sianipar et al. "Associations among smoking, IDH mutations, MGMT promoter methylation, and grading in glioma: a cross-sectional study", F1000Research, 2022

Publication

<1 %

31

Linjun Wang, Yiwen Xia, Tianlu Jiang, Ying Li, Fengyuan Li, Weizhi Wang, Diancai Zhang, Hao Xu, Li Yang, Zekuan Xu. "Neural invasion is an independent prognostic factor in young and lymph node negative gastric cancer patients underwent curative gastrectomy", Research Square Platform LLC, 2022

<1 %

Publication

---

Exclude quotes  On

Exclude matches  < 5 words

Exclude bibliography  On